

PATIENT PRESENTING CLINICAL SIGNS

Milo Olsen History: History of abdominal pain and inappropriate urination (urinating in house). Started ~1 year ago. rDVM initially concerned about bladder tumor. Started on NSAID and signs improved but still occasionally has urinary accidents. UA and bloodwork unremarkable.

SPECIES

Canine

COMPUTED TOMOGRAPHIC STUDY OF THE ABDOMEN

A high resolution pre- and post-contrast CT study of the abdomen is provided for review.

BREED

Chihuahua Mix

COMPUTED TOMOGRAPHIC FINDINGS

The serosal fat presents normal attenuation behavior. There is no evidence of peritoneal effusion or peritonitis.

SEX

Neutered Male

Both kidneys present within normal limits for size, shape and organ architecture. After contrast administration a bilaterally symmetric and uniform nephro- and pyelogram is noted. The urinary bladder wall is mildly thickened – most accentuated of the cranial pole, measuring up to 2.7 mm in width. The crura of the penis, at the caudal aspect of the ischial bone presents a mild heterogeneous contrast enhancement pattern – considered as physiological in the early post contrast phase.

AGE

5 Years

The adrenal glands are within normal limits for size, shape and organ architecture.

Both liver and spleen present with normal shape, even surface, uniformly attenuating parenchyma and homogeneous contrast enhancement, unremarkable.

INTERPRETED BY

Sebastian Schaub,
DVM Dr. med. vet.
DipECVDI

The pancreas is evenly contoured, the pancreatic parenchyma is homogeneous and presents uniform contrast enhancement.

The position, delineation, wall and content of the gastrointestinal tract are considered within normal limits throughout.

HOSPITAL NAME

Scottsdale VC

Level with the intervertebral disc spaces T11/T12 & T12/T13, mineralized disc material is protruding into the vertebral canal, distorting the ventral epidural space at the same level.

REFERRING VET

Dr. Magnussen

COMPUTED TOMOGRAPHIC DIAGNOSIS

- Mild thickened urinary bladder wall
- Intervertebral disc protrusion T11/T12 with possible dynamic spinal cord compression

INVOICE

16754

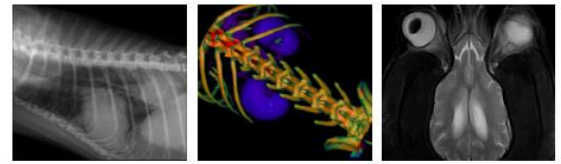
INTERPRETATION OF THE FINDINGS & FURTHER RECOMMENDATIONS

The thickened urinary bladder wall is concerning for cystitis or can still be a sequela to the low filling of the urinary bladder – correlate with findings of the urinalysis.

DATE

8/4/22

No additional clinically relevant abnormalities are appreciated.



PATIENT

Milo Olsen

SPECIES

Canine

BREED

Chihuahua Mix

SEX

Neutered Male

AGE

5 Years

INTERPRETED BY

Sebastian Schaub,
DVM Dr. med. vet.
DipECVDI

HOSPITAL NAME

Scottsdale VC

REFERRING VET

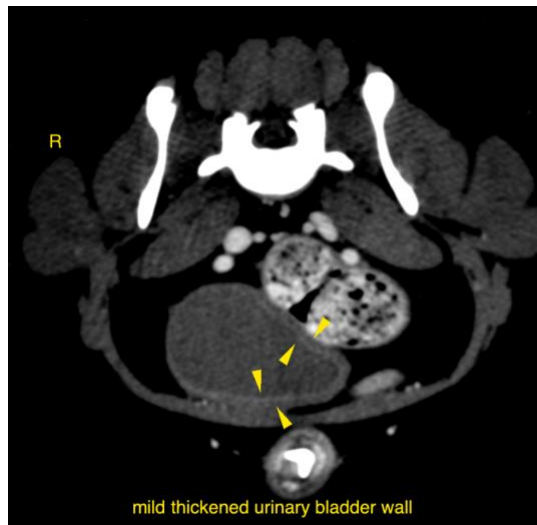
Dr. Magnussen

INVOICE

16754

DATE

8/4/22



The information and recommendations provided are based on the images presented by the referring veterinarian/sonographer. No evaluation can be communicated regarding pathology that was not visible in the image/video clips provided.

Thank you for this referral. If the clinical or image interpretation does not parallel your findings or if I can be of any further assistance please contact me.

Sebastian Schaub, Sebastian Schaub, DVM, Dr. med. vet. DipECVDI
sebast.schaub@gmail.com